

Annexin V – Affinity Assay – Apoptosis Detection System in Granular Cell Ameloblastoma

N Balaji¹, A Santha Devy², M K Sumathi³, S Vidyalakshmi⁴, G Sathish Kumar⁵, Shaloom D'Silva⁶

¹Professor & Head, Department of Oral and Maxillofacial Pathology, Teerthankar Mahaveer Dental College and Research Centre, Teerthankar Mahaveer University, Moradabad, Uttar Pradesh, India; ²Professor, Department of Oral and Maxillofacial Pathology, Indira Gandhi Institute of Dental Sciences, Pondicherry, India; ³Associate Professor, Department of Oral and Maxillofacial Pathology, Teerthankar Mahaveer Dental College and Research Centre, Teerthankar Mahaveer University, Moradabad, Uttar Pradesh, India; ⁴Senior Lecturer, Department of Oral and Maxillofacial Pathology, Indira Gandhi Institute of Dental Sciences, Pondicherry, India; ⁵Professor, Department of Oral and Maxillofacial Pathology, Indira Gandhi Institute of Dental Sciences, Pondicherry, India; ⁶Private Practitioner, Doha, Qatar.

ABSTRACT

Background: The aim of the study is to detect apoptosis in granular cell ameloblastoma by annexin v affinity assay, a novel technique.

Materials & Methods: Excisional biopsy of two patients with granular cell ameloblastoma were fixed in buffered formalin and later embedded in paraffin wax. Blocks were sliced into 3µm thick sections for routine histological and subsequent immunohistochemical examinations. For electron microscopic examination tissues were fixed in 2.5% glutaraldehyde. electron microscopic examination was carried out to find the nature of granularity in granular cell ameloblastoma which was finally confirmed by annexin v technique.

Results: Annexin v is a sensitive marker to detect early apoptosis. Fluorescence in granular cell clusters showed that apoptotic cell death is higher in granular cells. Both early and late events of apoptosis were identified in annexin v staining and electron microscopic study respectively.

Conclusion: Our study confirms that increased apoptotic cell death and subsequent phagocytosis is responsible for granular appearance of cells in granular cell ameloblastoma compared with that of conventional ameloblastoma.

Key Words: Affinity assay, annexin v, apoptosis, phagocytosis.

How to cite this article: Balaji N, Devy AS, Sumathi MK, Vidyalakshmi S, Kumar GS, D'Silva S. Annexin V – Affinity Assay – Apoptosis Detection System in Granular Cell Ameloblastoma. *J Int Oral Health* 2013; 5(6):25-30.

Source of Support: Nil

Conflict of Interest: None Declared

Received: 13th August 2013

Reviewed: 14th September 2013

Accepted: 19th October 2013

Address for Correspondence: Dr. Balaji N. Department of Oral and Maxillofacial Pathology, Teerthankar Mahaveer Dental College and Research Centre, Teerthankar Mahaveer University, Moradabad, Uttar Pradesh – 244001, India. Phone: +91 – 9444406009. Email: drbaalaji@gmail.com

Introduction

Ameloblastoma is an epithelial odontogenic tumour of the jaw and it exhibits diverse microscopic patterns which occur either singly or in combination with others. Granular ameloblastoma is an unusual variant of ameloblastoma which is characterized by nests of large, eosinophilic granular cells. These granular cells have been the subject of debate and about which there is controversy regarding its origin and nature. Previous studies have showed increase apoptotic cells

in granular cell ameloblastoma both immunohistochemically and ultrastructurally. Present study is an attempt to detect apoptosis in granular cell ameloblastoma by Annexin V Affinity Assay – A novel technique.

Ameloblastoma is most frequently encountered tumour arising from odontogenic epithelium and exhibits considerable histological variations.^{1,2} Granular cell variant of ameloblastoma shows granular

transmission of neoplastic cells.¹⁻⁴ Previous studies which includes ultrastructural,⁵⁻⁷ histochemical^{7,8} and immunohistochemical⁹⁻¹¹ methods have revealed that cytoplasmic granularity is caused by lysosomal overload, though the mechanism involved is poorly understood.

Apoptosis is a programmed, physiological mode of cell death that plays an vital role in tissue homeostasis as well as in oncogenesis.^{12,13} Apoptotic cells and Apoptotic related factors have been investigated in 2 germs and ameloblastoma suggesting that apoptotic reactions have important roles in tooth development and tumour growth.¹⁴⁻¹⁹

Numerous studies shown increased apoptotic cells and decreased expression of several apoptosis related factors such as Bcl – 2 family proteins and p53 protein cells in ameloblastoma.^{14,19} This study emphasis on a Noval technique Annexin V affinity assay system which detects early stages of apoptotic cell death in granular cell ameloblastoma.

Materials and Methods

Tissue Preparation:

Excisional Biopsy specimens from 2 patients with granular cell ameloblastoma were received and the clinical characteristics of the patients are shown in Table 1. Tumour tissues were fixed in buffered formalin and later embedded in paraffin wax. Tissues blocks were sliced into 3µm thick sections for routine histological and subsequent immunohistochemical examinations. Tissue sections were stained with H & E. For electron microscopic examinations, tissues were fixed in 2.5% glutaraldehyde and post fixed in 1%

Annexin V Affinity Assay:

This technique is designed to detect apoptosis by targeting for the loss of phospholipid asymmetry of the plasma membrane. Apoptotic cell death is accompanied by a change in plasma membrane structure by surface exposure of phosphatidylserine (PS) while the membrane integrity remains unchallenged. Surface exposed PS can be detected by its affinity for Annexin V, a phospholipid binding protein.

Annexin V was first reported by Bohn and colleagues²⁰ who isolated the proteins from human placenta and called it placental protein 4 (PP4) by Reutelingsperger et al²¹ who isolated it from umbilical cord by virtue of its anticoagulant activity and called it vascular – anticoagulant - α . After cloning and sequencing of the human Annexin V cDNA, the protein got its name because of its homology with family of Annexin proteins.²²⁻²⁴ Using fluorescently labeled annexin V it could be demonstrated apoptotic cells exposed PS at their outer membrane early after onset of the execution phase of apoptosis. PS appears at the outer leaflet of the plasma membrane, the integrity of which has not been compromised at this stage. PS exposures seem to last from early execution phase of apoptosis until the final stage at which the cell has broken up into apoptotic bodies.

Based on the phenomenon that PS is exposed during apoptosis and on the ability of annexin V to bind to PS with high affinity, Koopman et al²⁵ were the first to describe a method using extrinsically applied hapten (i.e. FITC or biotin) labeled annexin V to detect apoptosis. Annexin V is not able to bind to normal vital cells since the molecule is not able to penetrate the

Table 1

Case	Age	Sex	Location	Treatment
1	45	F	Molar-ramus	Extirpation
2	37	F	Molar - Premolar	Extirpation

osmium tetroxide, dehydrated in a graded series of ethanol & embedded in epoxy resin. Semithin sections were stained with 0.1% toluidineblue for light microscopy. Sections to be examined were selected and ultrathin sections were double stained with uranyl acetate and lead citrate.

phospholipid by layer. In the dead cells however the inner leaflet of the membrane is available for binding of extrinsically applied annexin V, since the integrity of plasma membrane is lost.

To discriminate between dead and apoptotic cells a membrane impermeable DNA stain, such as propidium

iodide (PI) is added simultaneously to the cell suspension. In this way vital, apoptotic and dead cells are discriminated on basis of a double labeling for annexin V and PI and analysed by fluorescence microscopy.²⁶

Results

Histological Features:

Specimens from both the granular cell ameloblastomas occurred in follicular pattern that showed odontogenic tumour in connective tissues stroma [Figure 1]. Follicle is lined by tall columnar cells and central core showing granular cell transformation [Figure 2]. The granular cell clusters showed pyknotic nuclei and bulky cytoplasm filled with eosinophilic granules.

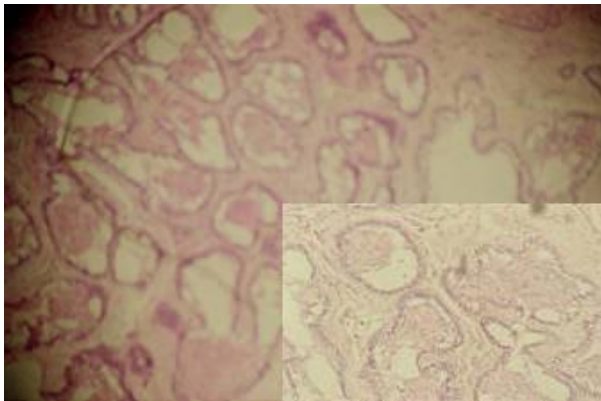


Figure 1: Odontogenic tumor in connective tissues stroma.

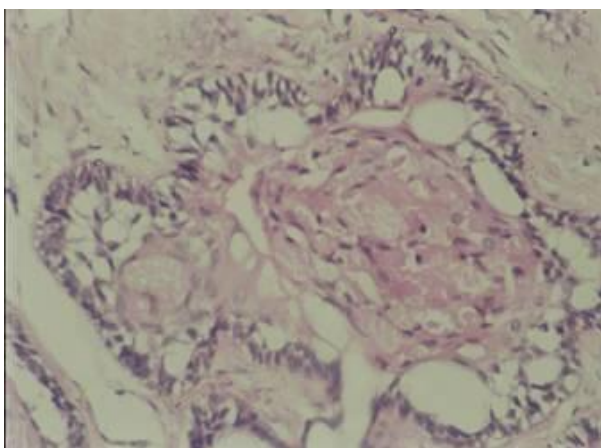


Figure 2: Tall columnar cells.

EM & Immunohistochemistry:

On EM examination, granular cell showed lysosomal aggregates [Figure 3]. Lysosomal vacuoles showed phagocytosed material. In the granular cell clusters,

apoptotic cell fragments with condensed chromatin is identified which were consequently phagocytosed by adjacent granular cells and degraded within lysosomes [Figure 4 & 5].

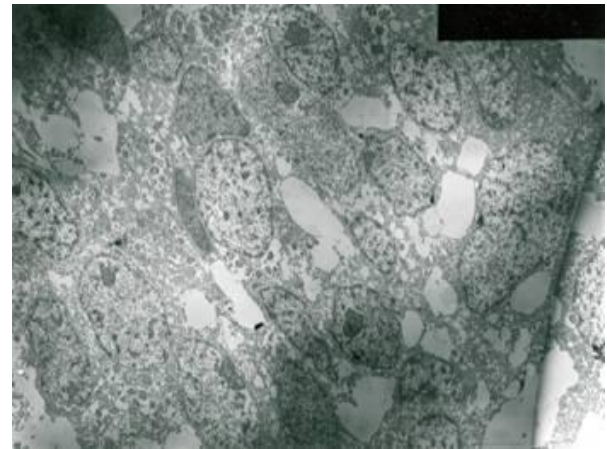


Figure 3: EM examination, granular cell showed lysosomal aggregates.

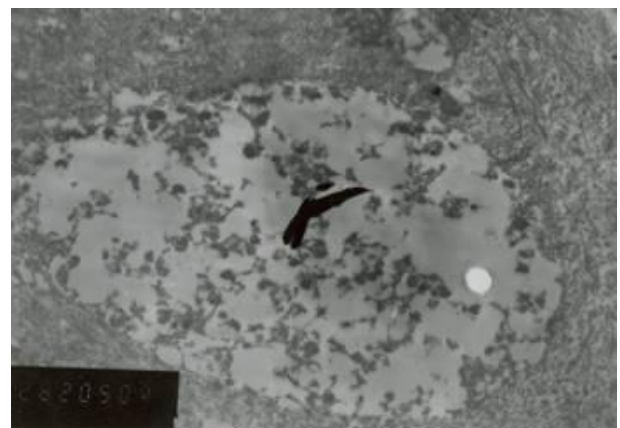


Figure 4: Lysosomal vacuoles showed phagocytosed material.




Figure 5: Granular cell clusters, apoptotic cell fragments with condensed chromatin is identified.

Immunohistochemically both granular and tall cells lining the follicle were positive for cytokeratin

indicating their epithelial origin. These cells were negative for vimentin, desmin and S-100. Granular cells stained positive for CD-68 but the tall columnar lining cells were negative.

Staining with Annexin V by immunofluorescence:

Viable cells maintained an asymmetric distribution of different phospholipids between outer and inner leaflets of plasma membrane. Loss of plasma membrane asymmetry is an important event in apoptosis, independent of the cell type. This resulted

in exposure of phospholipid from the inner phase to outer phase of plasma membrane. Phosphatidyl serine an aminophospholipid present in inner phase of the plasma membrane is exposed to the outer leaflet during apoptosis. This acts as a tag for its specific recognition by macrophages and for phagocytosis of the dying cell [Figure 6]. Annexin V is a calcium dependent protein that binds with phospholipid and this FITC tagged annexin V fluoresces as it stained positive for apoptotic bodies [Figure 7 & 8].

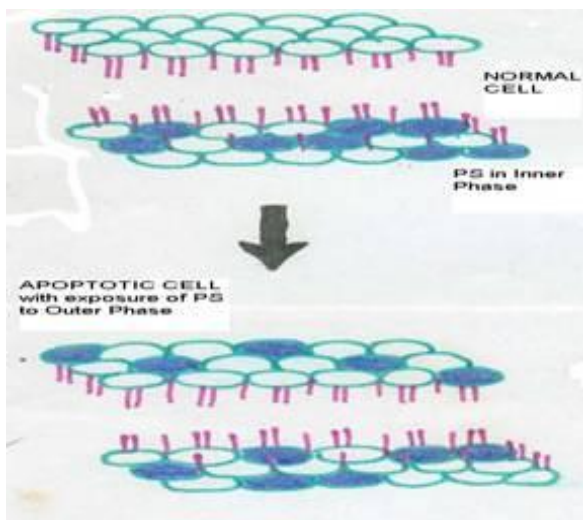


Figure 6: Phosphatidyl serine an aminophospholipid present in inner phase of the plasma membrane is exposed to the outer leaflet during apoptosis. This acts as a tag for its specific recognition by macrophages and for phagocytosis of the dying cell.

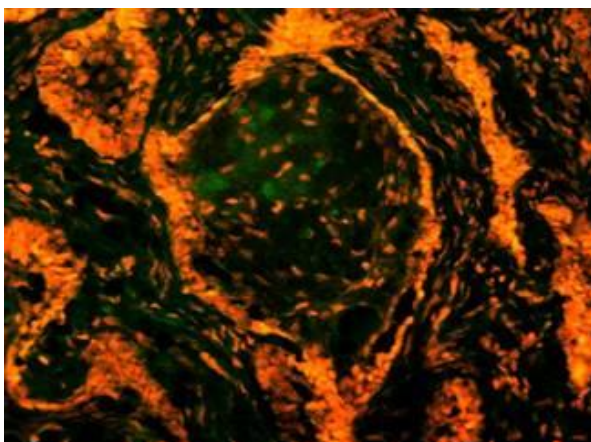


Figure 7: Annexin V is a calcium dependent protein that binds with phospholipid and this FITC tagged annexin V fluoresces as it stained positive for apoptotic bodies.

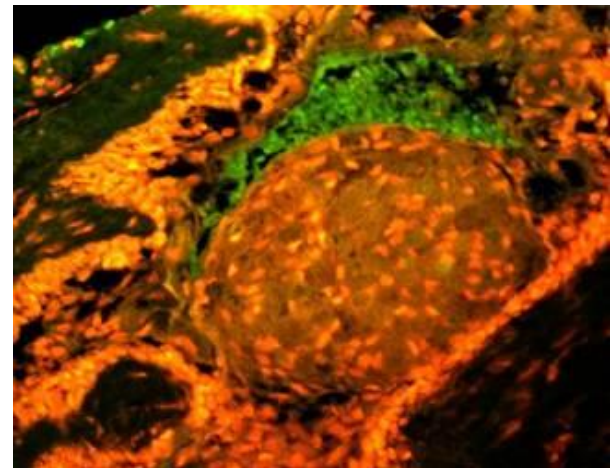


Figure 8: Annexin V is a calcium dependent protein that binds with phospholipid and this FITC tagged annexin V fluoresces as it stained positive for apoptotic bodies.

Discussion

Ameloblastoma sometimes exhibits granular transformation of cytoplasm usually occurring in central stellate reticulum like cells and this change often extends to peripheral columnar or cuboidal cells.¹⁻³ On routine histological examinations of the specimens, we found various quantities of granular cells in the neoplastic epithelial tissues. Also few apoptotic nuclear fragments were recognized in granular cell clusters.

Ultrastructural studies of granular cells ameloblastoma have revealed cytoplasmic granularity is associated with high content of lysosomes.⁵⁻⁷ Our EM examination also showed cytoplasmic lysosomal aggregation in both the cases. We also detected numerous apoptotic cell fragments with condensed nuclei in granular cell clusters and most of these fragments were

phagocytosed by adjacent neoplastic cells.

Both granular and tall columnar cells lining the follicles were positive for cytokeratine and negative for vimentin, desmin & S-100 which confirms epithelial origin of granular cells. In addition granular cells stained positive for CD-68.

Annexin V is a sensitive marker to detect early apoptosis. Apoptotic bodies identified in histopathological and EM sections were confirmed by staining with annexin V by immunofluorescence. Fluorescence in granular cell clusters showed that apoptotic cell death is higher in granular cells. Both early and late events of apoptosis were identified in Annexin V staining and EM study respectively. Thus our study confirms that it might be increased apoptotic cell death and subsequent phagocytosis, that is responsible for granular appearance of cells in granular cell ameloblastoma compared with that of conventional ameloblastoma.

Conclusion

Annexin V is a sensitive marker to detect early apoptosis. Apoptotic bodies identified in histopathological and EM sections were confirmed by staining with Annexin V by immunofluorescence. Though earlier studies have been conducted with quest of search for the nature of granularity of granular cell ameloblastoma, whether there is any possible correlation between the granularity of the tumour and prognosis, has to be yet answered. Further studies involving larger sample size would help in establishing the fact, which in turn, can be an aid in better therapeutic intervention.

References

- Huffman S, Jacoway JR, Krolls SO. Intraosseous and parosteal tumours of the Jaws. Washington, DC: Armed forces institute of pathology; 1987: p. 94 – 101.
- Kramer RH, Pindborg JJ, Shear M. WHO histological typing of Odontogenic tumours. Berlin: Springer – Verlag; 1992. p. 11 - 4.
- Hartman KS. Granular-cell ameloblastoma. Oral Surg Oral Med Oral Pathol Oral Radiol Endod 1974;38(2):241-53.
- Dina R, Marchetti C, Vallania G, Corinaldesi G, Eusebi V. Granular cell ameloblastoma. An immunocytochemical study. Pathol Res Pract 1996;192(6):541-6.
- Navarrette AR, Smith M. Ultrastructure of granular cell ameloblastoma. Cancer 1971;27(4):948-55.
- Tandler B, Rossi EP. Granular cell ameloblastoma: Electron microscopic observations. J Oral Pathol 1977;6(6):401-12.
- Nasu M, Takagi M, Yamamoto H. Ultrastructural and histochemical studies of granular-cell ameloblastoma. J Oral Pathol 1984;13(4):448-56.
- Mori M. Histochemical evaluation of enzymes in ameloblastic tumors--acanthomatous and granular-cell ameloblastoma. J Oral Surg 1970;28(11):825-31.
- Slootweg P, de Wilde P, Vooijs P, Ramaekers F. Oral granular cell lesions. An immunohistochemical study with emphasis on intermediate-sized filaments proteins. Virchows Arch A Pathol Anat Histopathol 1983;402(1):35-45.
- Stewart CM, Watson RE, Eversole LR, Fischlschweiger W, Leider AS. Oral granular cell tumors: a clinicopathologic and immunocytochemical study. Oral Surg Oral Med Oral Pathol 1988;65(4):427-35.
- Rühl GH, Akuamo-Boateng E. Granular cells in odontogenic and non-odontogenic tumours. Virchows Arch A Pathol Anat Histopathol 1989;415(5):403-9.
- Kerr JF, Wyllie AH, Currie AR. Apoptosis: a basic biological phenomenon with wide-ranging implications in tissue kinetics. Br J Cancer 1972;26(4):239-57.
- Carson DA, Ribeiro JM. Apoptosis and disease. Lancet 1993;341(8855):1251-4.
- Kumamoto H. Detection of apoptosis-related factors and apoptotic cells in ameloblastomas: analysis by immunohistochemistry and an in situ DNA nick end-labelling method. J Oral Pathol Med 1997;26(9):419-25.
- Slootweg PJ, de Weger RA. Immunohistochemical demonstration of bcl-2 protein in human tooth germs. Arch Oral Biol 1994;39(7):545-50.
- Nishikawa S, Sasaki F. DNA localization in nuclear fragments of apoptotic ameloblasts using anti-

- DNA immunoelectron microscopy: programmed cell death of ameloblasts. *Histochem Cell Biol* 1995;104(2):151-9.
17. Vaahtokari A, Aberg T, Thesleff I. Apoptosis in the developing tooth: association with an embryonic signaling center and suppression by EGF and FGF-4. *Development* 1996;122(1):121-9.
 18. Mitsuyasu T, Harada H, Higuchi Y, Kimura K, Nakamura N, Katsuki T, Kubota E, Toyoshima K, Ohishi M. Immunohistochemical demonstration of bcl-2 protein in ameloblastoma. *J Oral Pathol Med* 1997;26(8):345-8.
 19. Kumamoto H, Ooya K. Immunohistochemical analysis of bcl-2 family proteins in benign and malignant ameloblastomas. *J Oral Pathol Med* 1999;28(8):343-9.
 20. Inaba N, Sato N, Ijichi M, Fukazawa I, Nito A, Takamizawa H, Lüben G, Bohn H. The immunocytochemical location of two membrane-associated placental tissue proteins in human and cynomolgus monkey placentae. *Tumour Biol* 1984;5(2):75-85.
 21. Reutelingsperger CP, Hornstra G, Hemker HC. Isolation and partial purification of a novel anticoagulant from arteries of human umbilical cord. *Eur J Biochem* 1985;151(3):625-9.
 22. Iwasaki A, Suda M, Nakao H, Nagoya T, Saino Y, Arai K, et al. Structure and expression of cDNA for an inhibitor of blood coagulation isolated from human placenta: a new lipocortin-like protein. *J Biochem* 1987;102(5):1261-73.
 23. Kaplan R, Jaye M, Burgess WH, Schlaepfer DD, Haigler HT. Cloning and expression of cDNA for human endonexin II, a Ca²⁺ and phospholipid binding protein. *J Biol Chem* 1988;263(17):8037-43.
 24. Maurer-Fogy I, Reutelingsperger CP, Pieters J, Bodo G, Stratowa C, Hauptmann R. Cloning and expression of cDNA for human vascular anticoagulant, a Ca²⁺-dependent phospholipid-binding protein. *Eur J Biochem* 1988;174(4):585-92.
 25. Koopman G, Reutelingsperger CP, Kuijten GA, Keehnen RM, Pals ST, van Oers MH. Annexin V for flow cytometric detection of phosphatidylserine expression on B cells undergoing apoptosis. *Blood* 1994;84(5):1415-20.
 26. van Engeland M, Nieland LJ, Ramaekers FC, Schutte B, Reutelingsperger CP. Annexin V-affinity assay: a review on an apoptosis detection system based on phosphatidylserine exposure. *Cytometry* 1998;31(1):1-9.