

Telescopic overdenture - A case report

**Naveen YG* Patel Jayantilal R† Sethuraman Rajesh‡
Paranjay Prajapati§**

*M.D.S, Senior Lecturer, †M.D.S, Professor & Head,
‡M.D.S, Reader, §Post Graduate, Department of
Prosthodontics, K.M Shah Dental College, Vadodara,
Gujarat, India.
Contact: kadurnaveen@gmail.com

Abstract:

Preventive prosthodontics emphasizes the importance of any procedure that can delay or eliminate future prosthodontic problems. In the past when patients presented themselves as candidates for a denture with teeth that were badly broken down with periodontal involvement or without the ability to financially support an extensive restorative treatment, those teeth were extracted that could have been retained under more favourable conditions. Retention of the roots of one or more teeth for overdenture offers the patient a lot of advantages like better stability, proprioception, support among a few. The following case report is on telescopic over denture for maxillary arch and cast partial denture for mandibular partial edentulous arch.

Keywords: Telescopic overlay denture, Preventive prosthodontics, Coping and Sleeve

Introduction:

Preventive prosthodontics emphasizes the importance of any procedure that can delay or eliminate future prosthodontics problems. The overdenture is a logical method for the dentist to use in preventive prosthodontics.¹

The over denture is defined as a removable partial denture or complete denture that covers and rests on one or more remaining natural teeth, the roots of natural teeth and / or dental implants; a prosthesis that covers and is partially supported by natural teeth, natural tooth roots and / or dental implant². Various terms have been used to describe this treatment modality: overlay denture, telescoped dentures, tooth supported dentures,

P- ISSN
0976 – 7428

E- ISSN
0976 – 1799

*Journal of
International
Oral Health*

Prosthodontics

Case Report

Received: Oct, 2010

Accepted: Jan, 2011

Bibliographic listing:

EBSCO Publishing

Database, Index

Copernicus, Genamics

Journalseek Database,

Proquest, Open J Gate.

hybrid prosthesis, crown and sleeve prosthesis, and the superimposing dentures.³

Over denture therapy is essentially a preventive prosthodontic concept since it attempts to conserve the few remaining natural teeth. There are two physiologic tenets related to this therapy: the first concerns the continued preservation of alveolar bone around the retained teeth⁴ while the second relates to the continuing presence of periodontal sensory mechanisms⁵ that guide and monitor gnathodynamic functions.

Over dentures help to partly overcome many of the problems posed by conventional complete dentures like progressive bone loss, poor stability and retention, loss of periodontal proprioception, low masticatory efficiency, etc.⁶

Removable dentures attached by means of telescopic anchors are regarded to be a good clinical solution. This kind of restorations in patients with reduced and residual dentition gives an opportunity to reduce destructive rotational and horizontal occlusal forces by directing them more axially. It can also increase the stability of abutment teeth with periodontal disorders and protect them from pathologic migration, and, thus, may enhance the functional effect of the prosthetic treatment.

The concept of telescopic crown comes from optics, because it reminds the way of the optical telescope works with movement of two parallel cylinders. Telescopic crown is a system, which consists of two elements: internal crown, called male or primary crown or coping and external crown, called female or secondary crown or sleeve. The primary crown is cemented on the abutment and the secondary crown is attached to the removable denture and has the shape similar to natural tooth.

Case report:

A 67 year old male patient reported to the department of Prosthodontics, Crown & Bridge and Oral Implantology with the chief complaint of difficulty in chewing due to missing teeth and desire to improve esthetics. On intraoral examination teeth present were 11, 12, 17, 21, 22, 25, 31, 32, 33, 34, 37, 41, 42, 43, 44, and 45. The

teeth were firm with severe attrition of all maxillary remaining anterior teeth. Attrition was moderate with rest of the teeth. The edentulous span had favorable ridge with firmly attached keratinized mucosa. Further determination of the vertical dimension of occlusion (VDO) was achieved using Phonetics, Swallowing, patient preferences and facial appearance. It was determined that there was loss of VDO [Figure-1]. TMJ was normal.

Diagnostic casts were prepared via alginate impressions. Casts were mounted on a parallelometer and were analyzed on the basis of present undercuts, potential guiding surfaces and retentive areas of the remaining teeth for a possible removable partial denture. There was severe undercut in the anterior maxillary region and attrition in anterior maxillary teeth which needed esthetic restoration. Then Diagnostic cast were articulated in semi adjustable articulator using centric relation record and a face-bow transfer to evaluate inter arch space,

During the following visit, treatment options were discussed with the patient, including crown lengthening endodontic therapy and fixed restoration in maxillary anterior and either cast partial are implant supported prosthesis with respect to posteriors. After considering invasiveness, amount of time and financial aspect the patient elected to have, post & core and cast telescopic overlay denture with anterior composite veneers without labial flange (because of anterior severe undercut) in maxillary arch and cast partial denture for mandibular partially edentulous arch.

After taking consent from patient, he was sent for oral prophylaxis hygiene instruction and maintenance. Maxillary anterior teeth were then endodontically treated.

New Diagnostic mounting was done using bite rims for establishing vertical dimension (VD) in patient's mouth. Diagnostic tooth arrangements were made to established VD and the mandibular and maxillary interim overlay RPDs were fabricated with heat-polymerizing acrylic resin⁷. This interim dentures were worn for approximately

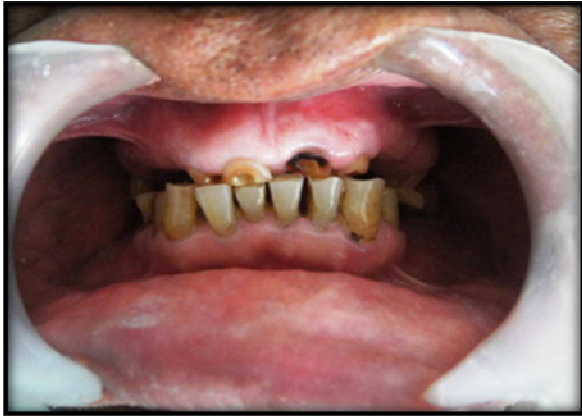

Fig 1: Pre-operative intra oral view showing attrition and decreased vertical dimension

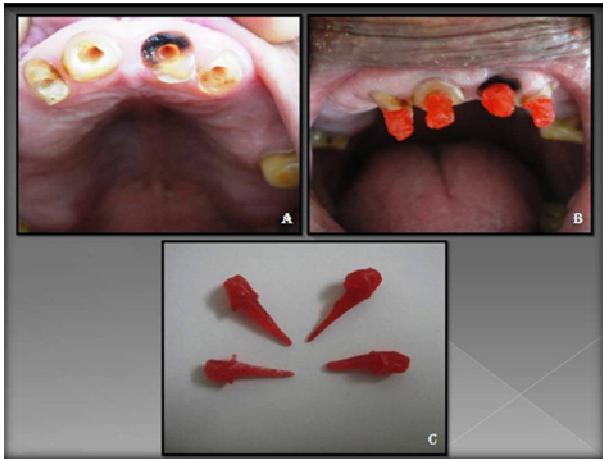


Fig 2: (a) Prepared maxillary anterior teeth for receiving the post and core, (b) Fabrication of post and core using direct technique, (c) Post and core patterns made using pattern resin

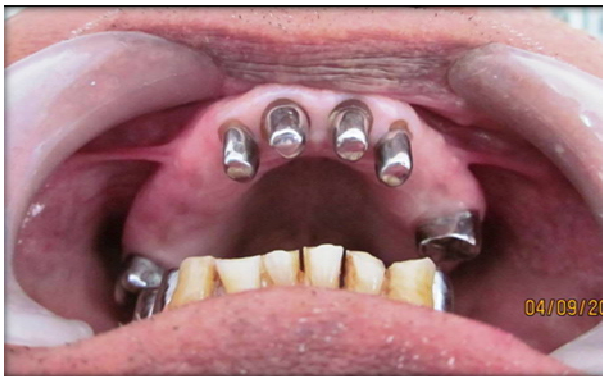


Fig 3: Intra oral view of cemented primary crowns on maxillary anteriors

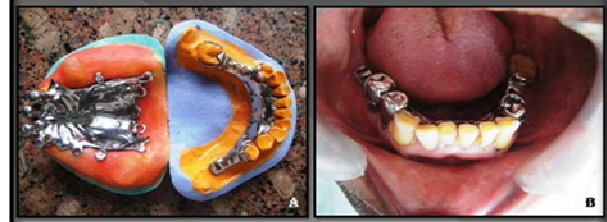


Fig 4: (a) Finished and polished frame work, (b) Mandibular frame work tried in patient's mouth

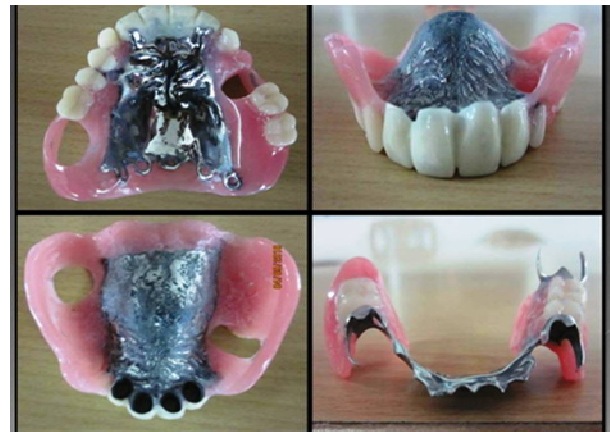

Fig 5: Finished and polished maxillary telescopic denture and mandibular cast partial denture

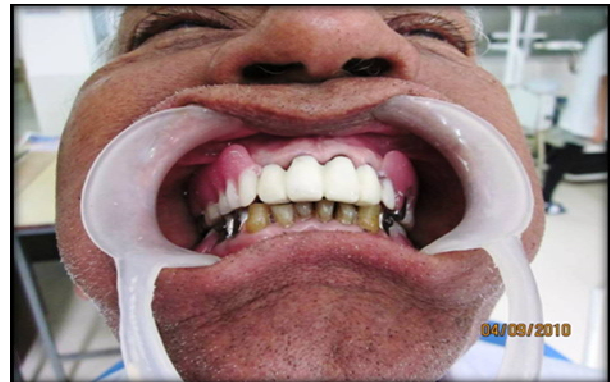

Fig 6; Intra oral view of prosthesis in occlusion




Fig 7: Post insertion view of the patient

6 weeks, during which occlusion was modified on the basis of phonetics, esthetic, patient comfort and ease of function.

After assessing endodontic therapy, maxillary anterior root canals were prepared for receiving cast metal post and core [Figure-2a]. Pattern resin was used to make patterns of post and core by direct technique [Figure-2b & 2c]. Pattern was casted using cast metal alloy finished polished and cemented. Also remaining maxillary and mandibular remaining posterior teeth were prepared for receiving metal crowns.

Impressions were made of both arches, Casts were mounted on the surveyor and wax pattern for primary coping for maxillary anterior and metal crowns for maxillary posteriors were fabricated keeping mind that they are parallel each other. Lower posterior wax patterns were made by incorporating rest seats in them. Wax patterns were invested, cast, finished and modified on the surveyor for parallelism, castings were polished and cemented in patient mouth [Figure-3].

Definitive impressions were made using a custom tray and monophase impression material cast were made, undercuts were blocked out and refractory casts were prepared. On mandibular refractory cast patterns for cast partial denture were made. On maxillary refractory cast pattern of telescopic framework was prepared, to which the pattern for maxillary metal framework was attached. To facilitate the acrylic bond with the metal framework serrations were placed on labial surface of the secondary coping covering the anterior teeth. The patterns were casted in chrome cobalt alloy, finished [Figure-4a] and evaluated intraoral for fit, retention and stability [Figure-4b].

Maxillomandibular relationships were made with frameworks in position, and definitive casts were mounted on the semi-adjustable articulator. Shade selection was done, indirect composite veneer was build up was done in the esthetic zone⁸, and

artificial acrylic resin teeth were arranged in the edentulous posterior regions. Into a bilateral balanced occlusal scheme. Dentures were tried in patient's mouth, and processed in heat cure acrylic resin. Dentures were finished, polished [Figure-5] and inserted [Figure-6]. Occlusion was evaluated and adjusted, Postoperative instructions on how to insert the prostheses and also was provided with instruction on adequate oral hygiene maintenance. After minor adjustments during post insertion visits [Figure-7], the patient was placed on a 6 month recall.

Discussion:

It is a documented fact that after the loss of the teeth the residual alveolar ridge undergoes rapid loss in all dimensions. The phenomenon of residual ridge resorption (RRR) following removal of teeth has been well observed and documented in literature.^{9,10} While the bone loss following the removal of teeth is stated to be rapid, progressive, irreversible and inevitable, it is equally well observed that bone is maintained around standing teeth and implants.^{10,11}

Over denture therapy constitutes essentially a preventive prosthodontics concept as it endeavors to preserve the few remaining teeth and the supporting structures^{1,2}. The teeth which are too weak to support a fixed partial denture and are considered unsuitable to support a removable partial denture can often at times be usefully conserved and suitably modified to act as abutments under over dentures for useful span of time.

The telescopic overlay denture system used in This case revealed a long lasting usefulness in the prosthetic treatment of the patient with reduced dentition. Similar clinical observations were also described in reports made by other authors¹².

It has been observed by many authors that positive results of prosthetic treatment with telescopic dentures in patients with reduced dentition and inflammation of periodontium¹³ There are many

advantages of telescopic crowns like axial load of the tooth and full covering of the abutment (on the contrary to clasps), which may reduce tilting forces with their negative influence on abutment supporting tissues. The axial forces stimulate periodontal tissues and alveolar bone. They also provide indirect splinting influence, easy oral hygiene maintenance and easy ways of repair^{14,15}.

Since there was an anterior undercut in maxillary ridge it was difficult to obtain a single path of insertion along with the overlay coping. So an anterior flange less denture was planned. If the labial flange had to be given, it would necessitate excessive anterior block out, in turn resulting in excessively bulky anterior flange. Further the flange would have interfered in esthetic and phonetics.

Indirect composite resin veneering was used to restore anterior teeth in the esthetic region. Since indirect composite satisfies almost all qualities required for a anterior restorative material like shear bond strength, color stability, longevity^{16,17}

As the over denture status of the prosthesis and its benefits to the patient depend solely on the continued retention of the underlying abutments, it becomes obligatory to periodically monitor their health and institute necessary steps to prolong their useful span. Here in lies the importance of periodical recall and review and patient motivation which makes over denture therapy a continued service.

Conclusion:

Although the telescopic over denture is not a panacea, if fabricated well with good clinical and laboratory Expertise, maintained with excellent care, then each telescopic over denture treatment can be a successful one.

References:

1. John J Sharry. Complete Denture Prosthodontics. Third edition, New York, McGraw-Hill Book Co., 1974.

2. Glossary of Prosthodontic terms. J Prosthet Dent 2005; 94: 10-92
3. Dhir RC. Clinical assessment of the Overdentures therapy. J Indian Prosthodont Soc 2009; 5: 187-92.
4. Prince IB. Conservation of the supporting mechanism. J Prosthet Dent 1965; 15: 327.
5. Yalisove IL. Crown and sleeve coping retainers for removable partial prosthesis. J Prosthet Dent 1966; 16: 1069-85.
6. Reitz PV, Weiner MG, Levin B. An overdenture survey: Preliminary report. J Prosthet Dent 1977; 37: 246-58.
7. Chen MS, Eichhold WA, Welker WA, Chien CC. Simplicity in interim tooth-supported removable partial denture construction. J Prosthet Dent 1985; 54: 740-4.
8. Kolodney h jr, akerly wb. A composite resin veneer occlusal surface on an overlay partial denture. Compendium 1991; 26: 617-20
9. Toolson LB, Smith DE. A two year longitudinal study of overdenture patients, Part 1: Incidence and control of caries on overdenture abutments. J Prosthet Dent 1978; 40: 486-91.
10. Tallgren A. Positional changes of complete dentures—A seven year longitudinal study. Acta. Odontol. Scand. 1969; 27: 539-61.
11. Tallgren A. The continuing reduction of the residual alveolar ridges in complete denture wearers: a mixed longitudinal study covering 25 years. J Prosthet Dent 1972; 27: 120-32.
12. Vin Y, Pan S, Feng H. Three dimensional finite element analysis and comparison of stress distribution in overdentures supported with bar attachments and telescopic crowns. Chin J Dent Res. 1992; 2: 21-30.
13. Hou GL, Tsai CC, Weisgold AS. Periodontal and prosthetic therapy in severely advanced periodontitis by use of the crown and sleeve coping telescope denture. A longitudinal case report. Aust Dent J. 1997; 42: 169-74.
14. Langer Y, Langer A. Tooth supported telescopic prostheses in compromised dentitions: A clinical report. J. Prosthet Dent. 2000; 84: 129-32.

15. Dąbrowa T, Panek H, Napadłek P. 8-Year Clinical Observation of Telescopic Anchors Applied in Removable Dentures - Case Report. Dent Med Probl. 2007; 44: 521-5
16. Jones RM, Moore BK, Goodacre CJ, Munoz-viveros CA. microleakage and shear bond strength of resin and porcelain veneers bonded to cast alloys. J Prosthet Dent 1991; 65: 221-8
17. Jones RM, Goodacre CJ, Moore BK, Dykema RW. A comparison of physical properties of four prosthetic veneering materials. J Prosthet Dent 1989; 61: 38-4.

Source of Support: Nil

Conflict of Interest: No Financial Conflict