

## A Denture with Hollow to Make Weight Shallow: A Case Report with a New Putty Method

H S Indrakumar<sup>1</sup>, G S Amarnath<sup>2</sup>, Girish R Shavi<sup>3</sup>, A Hariprasad<sup>4</sup>, S Mohammed Hilal<sup>4</sup>, M Anand<sup>5</sup>

### Contributors:

<sup>1</sup>Assistant Professor, Department of Prosthodontics, Mathrusri Ramabai Ambedkar Dental College & Hospital, Cooke Town, Bengaluru, Karnataka, India; <sup>2</sup>Professor and Head, Department of Prosthodontics, Mathrusri Ramabai Ambedkar Dental College & Hospital, Cooke Town, Bengaluru, Karnataka, India; <sup>3</sup>Professor, Department of Public Health Dentistry, People's College of Dental Sciences & Research Centre, Bhanpur, Bhopal, Madhya Pradesh, India; <sup>4</sup>Reader, Department of Prosthodontics, Mathrusri Ramabai Ambedkar Dental College & Hospital, Cooke Town, Bengaluru, Karnataka, India; <sup>5</sup>Senior Lecturer, Department of Prosthodontics, Mathrusri Ramabai Ambedkar Dental College & Hospital, Cooke Town, Bengaluru, Karnataka, India.

### Correspondence:

Dr. Indrakumar HS. Department of Prosthodontics Mathrusri Ramabai Ambedkar Dental College & Hospital, 1/36, Cline road, Cooke Town, Bengaluru - 560 005, Karnataka, India. Email: indrakumar.hs@gmail.com

### How to cite the article:

Indrakumar HS, Amarnath GS, Shavi GR, Hariprasad A, Hilal SM, Anand M. A denture with hollow to make weight shallow: A case report with a new putty method. J Int Oral Health 2014;6(4):92-4.

### Abstract:

To minimize the weight of the prosthesis various techniques that create a hollow prosthesis have been known. There are a lot of drawbacks of these techniques as they are complex, time consuming, and of high cost. Here is a technique that utilizes putty material for fabricating hollow denture prosthesis.

**Key Words:** Edentulous, hollow, prosthesis, weight

### Introduction

Prosthetic rehabilitation may be a problem with the extremely resorbed maxillary edentulous ridges.<sup>1</sup> This problem is due to increased inter-arch space between the maxillary and mandibular residual ridges. It decreases the retention and resistance because of the heavy maxillary complete denture.

To minimize the weight of the prosthesis various techniques that create a hollow prosthesis have been known.<sup>2</sup> There are a lot of drawbacks of these techniques as they are complex, time-consuming, and of high cost. Here is a technique that utilizes putty material for fabricating hollow denture prosthesis.

### Case Report

A patient of age 78 years had come to our dental institution for the replacement of missing teeth. On clinical examination, it was found that the maxillary and mandibular ridges were

resorbed and there was increased inter arch space. Treatment was planned to fabricate maxillary hollow denture. Primary and secondary impressions of the maxillary residual ridge were made, and the denture was fabricated till the trial denture stage. Up to trial appointment the clinical steps are similar to a conventional denture. Duplication of the trial denture is done with the agar reversible hydrocolloid impression material. The impression of the trial denture is poured with die stone (DPI). Now the trial denture is processed until the wax elimination stage.

By using the thermoplastic sheet (Bio-star) of 0.3 mm duplication of the trial denture maxillary cast is done, and the template is made (Figure 1).

On the maxillary cast after dewaxing the putty index of addition silicone (aquasil) is adapted (Figure 2).

Indexed putty is trimmed with a bur to create 2-3 mm of space between the putty index and template. Additional 1 mm space is provided further for the tooth accommodation. The putty is fixed on the denture base with fevikwik. The height and space available between the bio-star template and the putty index is determined using reamers or files to accommodate heat acrylic resin and teeth (Figure 3).

The original cope is placed on the drag, and flask closure is checked. The acrylic resin is now polymerized conventionally. Using a periodontal probe adequate thickness of the resin around the teeth during packing is checked. Processed denture is deflasked as usual (Figure 4).

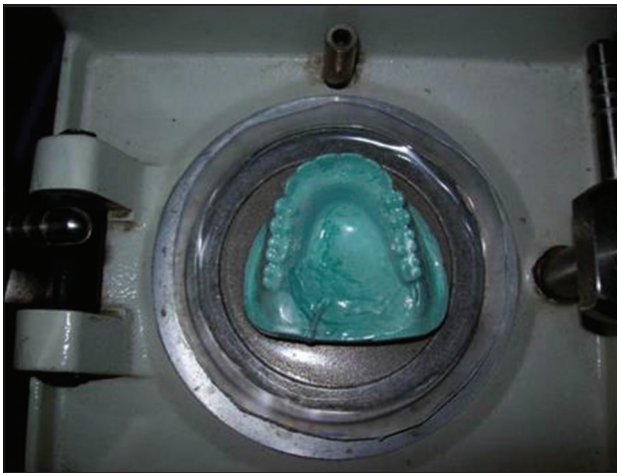Occlusion is adjusted by remounting on an articulator. Two openings are made with a bur (straight fissure and round) at the distal region of the most posterior teeth (Figure 5). The silicone putty is removed by scraping with a sharp instrument. The putty is removed, and two coverings are fabricated using transparent self-cure resin (DPI). Disinfection of the cavity is done (Povidone Solution, India). Coverings are attached into the position using self-cure acrylic resin (DPI).

Denture is polished and verified by immersing the denture in water for the seal (Figure 6). The seal is adequate if there are no air bubbles.

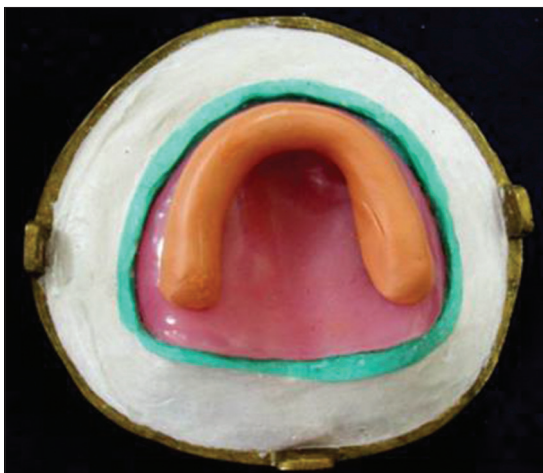### Discussion

It has been said from hundreds of years that the weight of the denture increases the retention and stability of the lower

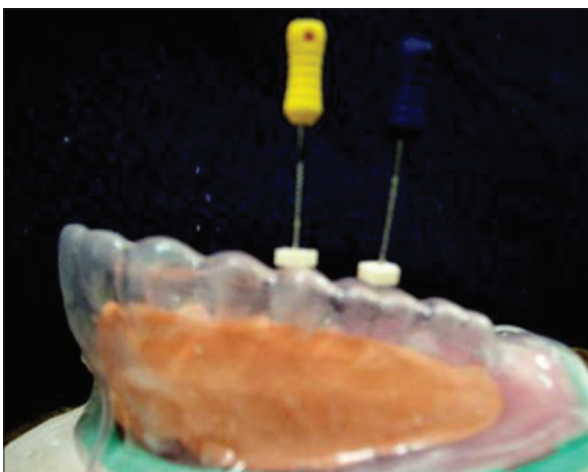
complete denture.<sup>3</sup> The heavy and light weight mandibular complete denture was compared with the retention, stability, and comfort. It was showed that the retention or stability was not affected by the metal base, which was used to increase the weight of the mandibular denture.



**Figure 1:** Duplicated cast of trial denture with clear matrix adapted.



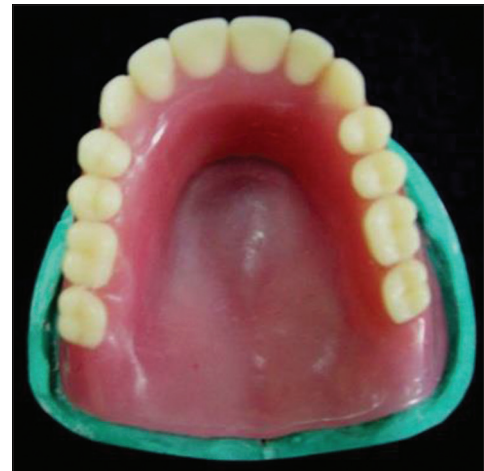**Figure 2:** Silicone putty spacer adapted.



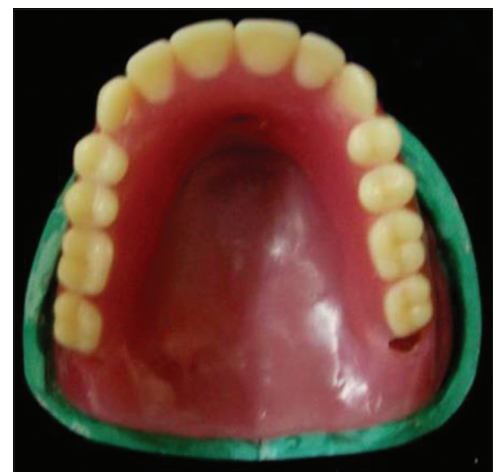**Figure 3:** Endo file with rubber stop to measure the space between matrix and the processed resin.

The dentures were fabricated over the hard palate of the osteoporotic rats to determine the histopathological changes of the denture bearing structures of the oral cavity.<sup>4</sup> It was revealed that there was bone resorption on the periosteal surface of the bone under the denture bearing surface due to continuous pressure.

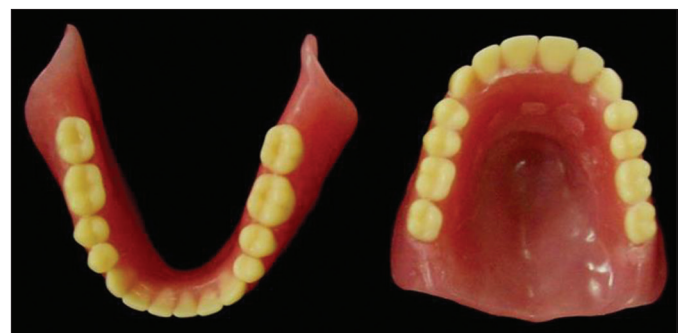Bone resorption starts just after total teeth extraction from there it is a continuous process.<sup>5</sup> It is difficult to predict the individual variation in the rate of resorption. Even now it is less understood because of its complex etiology. It is strongly



**Figure 4:** Processed denture with putty spacer inside.



**Figure 5:** Windows created to remove the silicone putty spacer.



**Figure 6:** Windows closed with autopolymerizing resin.

believed now that weight of the denture contributes for the residual ridge resorption. To counter act resorption, various methods and techniques have been evolved to reduce the weight of the denture.

In this method, the putty and clear matrix controls the thickness of acrylic resin and further an even thickness of the resin is maintained to prevent any deformation during flasking. Recontouring of the putty using bur before packing will further controls the uniform thickness of the denture. Since it is stable, easy to remove, easy to trim, the addition silicone putty material is the most desirable spacer material that can be used for the fabrication of the light weight dentures.

### **Conclusion**

The main objective of this technique is to make the denture

lighter and thereby to increase the retention and resistance form and preserve the residual ridge.

### **References**

1. O'Sullivan M, Hansen N, Cronin RJ, Cagna DR. The hollow maxillary complete denture: A modified technique. *J Prosthet Dent* 2004;91(6):591-4.
2. Hurtado AJ. Internally weighted mandibular dentures. *J Prosthet Dent* 1988;60(1):122-3.
3. Ohkubo C, Hosoi T. Effect of weight change of mandibular complete dentures on chewing and stability: A pilot study. *J Prosthet Dent* 1999;82(6):636-42.
4. Holt RA Jr. A hollow complete lower denture. *J Prosthet Dent* 1981;45(4):452-4.
5. Fattore LD, Fine L, Edmonds DC. The hollow denture: An alternative treatment for atrophic maxillae. *J Prosthet Dent* 1988;59(4):514-6.