

# $\beta$ Thalassemia major: A case report

Tejavathi Nagaraj\* Umashree N† Achut R Devarhubli‡  
Shankara SN§

\*M.D.S, Professor and Head, †M.D.S, Senior Lecturer,  
Department of Oral Medicine and Radiology, ‡M.D.S,  
Professor, Department of Prosthodontics, §M.D.S,  
Professor, Department of Conservative and Endodontics,  
Sri Rajiv Gandhi College Of Dental Sciences, Bangalore,  
India.

Contact: tejavathi.6@gmail.com

## **Abstract:**

Beta thalassemia has a spectrum of varied manifestations and complications. Survival is associated with various multisystem complications primarily caused by chronic anemia, iron overload, adverse effects of chelation, and transfusion-associated infections. Thus, a disease that starts merely as hemolytic anemia attains the dimension of a chronic disease with multisystem involvement. The importance of thalassemia is masked by infections and nutritional deficiencies. We need to develop preventive strategies like pre-marital screening, genetic counseling, and ante-natal diagnosis. Apart from early diagnosis, there is a need to increase the therapeutic facilities like blood transfusions, chelation therapy, and bone marrow transplant. It is really a great challenge and needs an organized plan for action.

Keywords: Thalassemia major, hemolytic anemia, blood transfusion.

## **Introduction:**

Thalassemia is among the most widely distributed genetic disorder to cause major public health problem.  $\beta$  Thalassemia is a severe hemolytic anemia occurring as a result of deficient or absent synthesis of  $\beta$  globin chain of Hb A.<sup>1</sup> This disorder is associated with a remarkable clinical heterogeneity with striking differences in hematological manifestations among different ethnic groups. The molecular basis of Thalassemia has been studied worldwide; more than 200 different mutations in the  $\beta$  globin gene have been

*P- ISSN*  
*0976 – 7428*

*E- ISSN*  
*0976 – 1799*

*Journal of*  
*International*  
*Oral Health*

Oral Medicine

Case Report

*Received: April, 2011*  
*Accepted: August, 2011*

## **Bibliographic listing:**

EBSCO Publishing  
Database, Index  
Copernicus, Genamics  
Journalseek Database,  
Proquest, Open J Gate.

reported. It was also found that types of mutations are ethnic specific.<sup>2</sup> Thalassemia is considered to be the most common genetic disorder worldwide.<sup>1</sup> The condition was first described by Thomas B Cooley and Pearl Lee in 1925; and appeared in an article entitled “A series of cases of Splenomegaly in children with anemia and peculiar bony changes”.<sup>3</sup> The term Thalassemia was first used by Wipple and Bradford in 1932, derived from greek word “*thlassa*” meaning sea and “*haemia*” meaning blood.<sup>2</sup> Thalassemia imposes a significant intrusion in the lives of the patients and their families. The effects are many, sweeping from financial hardships and absence from school to significant issues with self-image and self esteem. If this disease continues to pass on from one generation to the other, it may take the form of a disaster. There is a large increase in the number of Thalassemia patients due to lack of genetic counseling and genetic screening in countries like ours. There is a growing concern that Thalassemia may become a very serious problem in the next 50 years, one that will burden the world’s blood bank supplies and the health system in general. The treatment available for Thalassemia is not satisfactory; hence prevention of disease by carrier detection and prenatal diagnosis is very essential.<sup>3</sup>

The Thalassemias are widespread with about 5% of the world population affected by it. It is most prevalent around the Mediterranean Sea i.e. countries like Greece, Italy, Turkey and North African countries.<sup>3</sup> It is also seen in Saudi Arabia, Iran, Afghanistan, Pakistan, India and south East Asian countries like Thailand and Indonesia. The prevalence is highest in Italy, Greece and Cyprus.<sup>3</sup>

$\alpha$  Thalassemia is not a significant problem in India because the severe  $\alpha$  deletions are less common in this region. The carrier rate of  $\beta$  Thalassemia varies from 3-17%.<sup>4</sup> In India, prevalence of Thalassemia is very high among certain communities like Punjabi, Sindhi, Gujarati, Bengali, Parsee, Lohana and certain

tribes, i.e. northern, western and Eastern parts, while it is much less in the south of India.<sup>5</sup>

In a cross-sectional study of 50 patients with thalassemia major by Mahshid Mehdizadeh, Mojdeh Mehdizadeh, Gholamreza Zamani in 2007, it was concluded that Thalassemia was associated with higher rates of dental caries and malocclusion.<sup>6</sup> In yet another study Thalassemic patients exhibited a skeletal class II malocclusion, retrognathia of the mandible, a short height of the ramus, an increase in anterior facial height, and a decrease in posterior facial height.<sup>7</sup> Here is a case report of an 18-year-old male with classical clinical presentation of  $\beta$  Thalassemia major disorder.

### Case report:

A 18 year old male reported to our Department of Oral Medicine & Radiology, with a chief complaint of decayed upper left back tooth, not associated with pain or swelling. Patients’ medical history revealed that he is a known case of  $\beta$  Thalassemia major since he was one and a half year old, for which he has been undergoing blood transfusion since then. Patient had undergone Splenectomy 2 years back. However both the parents could not be traced for a detailed family history, patient has no siblings too. On general examination, he was under-built, under-nourished with a short stature, with evident icterus, and yellow tinged fingernails. His skin was ashen grey in color. Head and Neck examination revealed depressed cranial vault, frontal bossing, maxillary expansion, retracted upper lip and saddle nose; all together depicting the classical “*Chipmunk facies*”.<sup>5</sup> Intraoral examination revealed bilateral maxillary expansion, proclined upper anterior teeth and grossly decayed 26; also noted was a yellowish tinge at the junction of hard and soft palate (Figure 1: A-E).

The patient was then subjected for haematological and radiological examination. The impression drawn from the peripheral smear study was that of hemolytic anemia favoring Thalassemia going for hemolytic crisis.

Later Hb electrophoresis was done which too was in favor of  $\beta$  Thalassemia major.

### **Radiographic Findings:**

The maxillary and mandibular occlusal views (Figure 2.A and B) revealed enlargement of marrow spaces with widened trabeculae. The lateral cephalograph showed the classical “*hair on end*” appearance. The Orthopantomograph revealed thinning of cortical borders and short spiky roots. (Figure 3. A and B).

### **Discussion:**

Thalassemia syndromes are characterized by various degrees of ineffective hematopoiesis and increased hemolysis.<sup>8</sup> As a result of chronic transfusion, which is necessary for these patients, excessive iron load and hemochromatosis develop, and many organ systems, especially cardiovascular and endocrine systems, will be affected.<sup>9</sup> Extramedullary hematopoiesis also results in bony deformities. In the face, enlargement of jaw and its alveolar process produce various and serious malocclusion stages.<sup>5</sup>

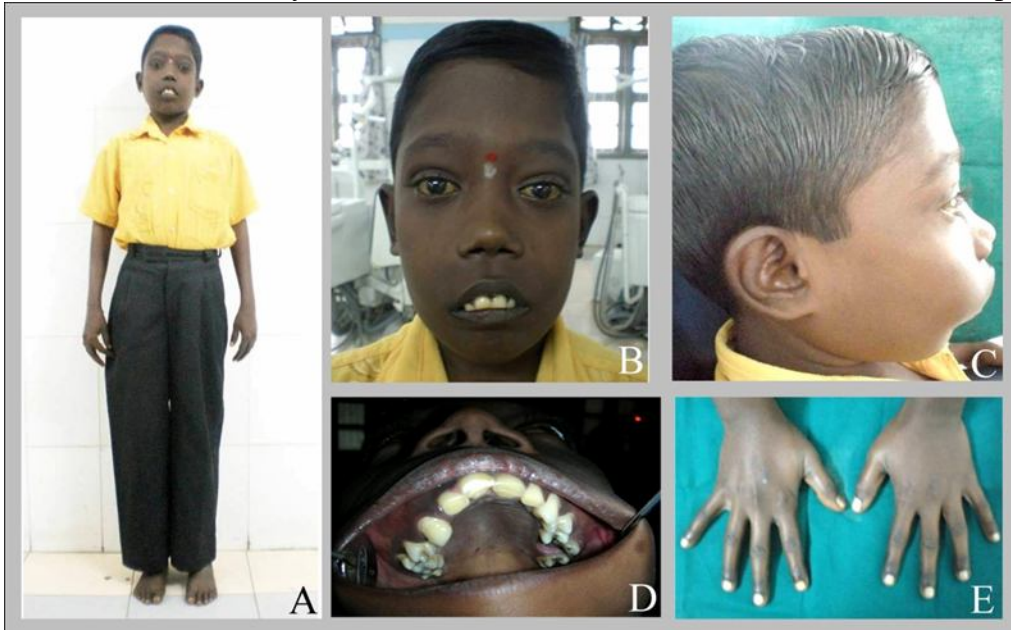
Clinical types: There are three variants of homozygous  $\beta$  Thalassemia distinguishable on the basis of the severity of expression. These are  $\beta$  Thalassemia minor,  $\beta$  Thalassemia intermedia and  $\beta$  Thalassemia major.<sup>10</sup>  $\beta$  Thalassemia minor is mild and usually asymptomatic, the only manifestation is hypochromic, microcytic anemia. Thalassemia intermedia is a condition intermediate between the minor and the major forms.<sup>11</sup>  $\beta$  Thalassemia major patients are born healthy; however symptoms such as anemia, hepatosplenomegaly, growth retardation, jaundice and bone changes usually develop within the first year of life, thus making regular blood transfusion and iron chelation therapy necessary for survival.<sup>10,11</sup> The clinical course of  $\beta$  Thalassemia major in most cases is severe. It is a life threatening condition characterized by severe, hypochromic and microcytic anemia. Endocrine abnormalities encountered in  $\beta$  Thalassemia major are evident during the

second decade of life and are secondary to the chronic iron overloading.<sup>5,7</sup> In addition seen are the skeletal changes due to hypertrophy and expansion of erythroid marrow, susceptibility to infections and cardiac failure following iron deposition in the myocardium. In addition thromboembolic phenomena, both venous and arterial are common in patients who undergo splenectomy.<sup>5,10</sup>

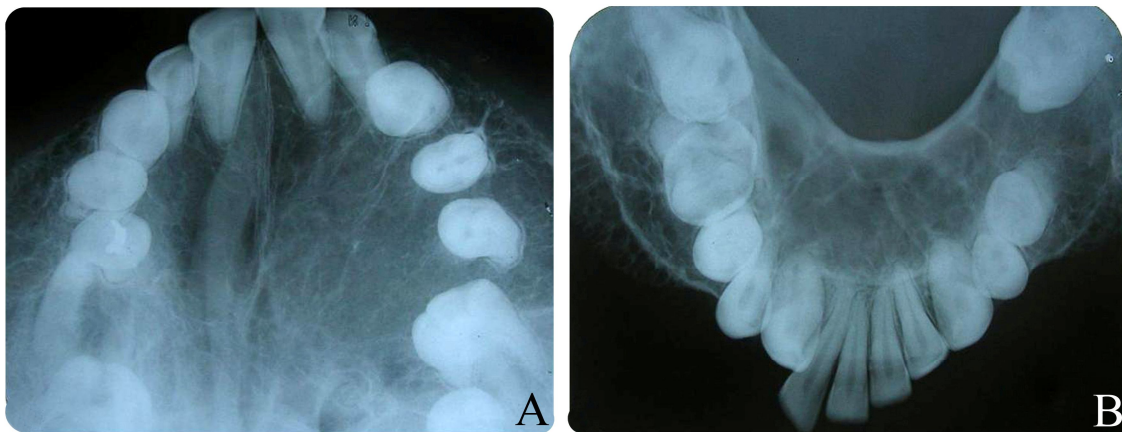
Extreme hypertrophy of the erythroid marrow in medullary and sometimes extramedullary sites is a well-known feature in Thalassemia major.<sup>7</sup> Involvement of the facial skeleton resulting in severe disfigurement has been described in several reports.<sup>12</sup> Under the influence of the disorder the typical facial appearance develops; high and bulging cheek bones, retraction of the upper lip, protrusion of the anterior teeth and spacing of other teeth, overbite or open-bite, and varying degrees of malocclusion.<sup>11,13</sup> The skeletal changes are the result of proliferation of the bone marrow in the facial skeleton. This proliferated marrow is extensively used as an ancillary hematopoietic organ to compensate for the chronic hemolysis. Usually the mandible becomes less enlarged than the maxilla. The dense cortical plates of the mandible apparently prevent the expansion. The bony changes may occur early in life and tend to persist, particularly in skull.<sup>10,12</sup> In addition, a tint of lemon color is observed in oral mucosa due to existing bilirubin produced by the decomposition of red cells.<sup>10,14</sup>

Radiological changes are not apparent until one year of age. These include large bone marrow spaces, one of the most important radiographic features of Thalassemia.<sup>16</sup> This enlargement is explained by the fact that, when ineffective erythropoiesis damages the RBC membrane leading to severe anemia, the body responds by increasing the production of Red Blood Cells, consequently causing expansion of the bone marrow up to 15-30 times the normal amount.<sup>4,17</sup> The skull radiograph shows the increased diploid space and arrangement of trabeculae in the vertical rows, causing “*hair on*

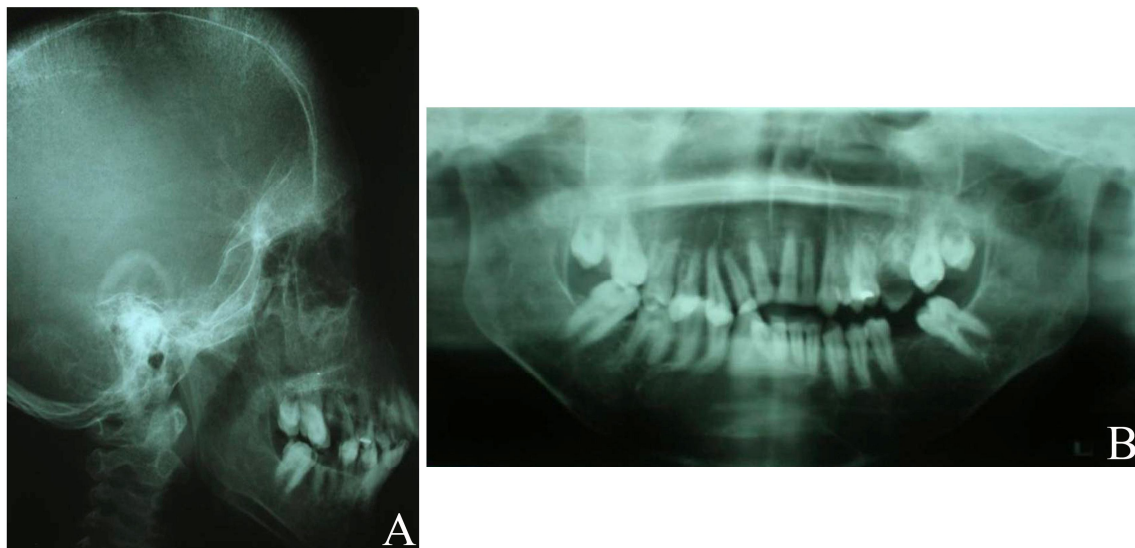
end” appearance.<sup>4</sup> Small maxillary sinuses are also attributed to bone marrow expansion



**Figure 1:** A. Showing the general development of the patient, B. Showing icterus in the eyes, C. Showing classical “*Chipmunk facies*” with depressed cranial vault, frontal bossing, maxillary expansion, retracted upper lip and saddle nose D. Showing yellowish tinge at the junction of hard and soft palate E. Showing yellow tinged fingernails.



**Figure 2:** A. maxillary and B. mandibular occlusal radiograph reveals enlargement of marrow spaces with widened trabeculae.



**Figure 3: A. The lateral cephalograph showing the classical “hair on end” appearance. B. The OPG showing thinning of cortical borders and short spiky roots.**

causing hyperplasia of the alveolar processes of maxilla at the expense of the sinuses normal volume.<sup>18</sup> The findings are thin cortex, spiky shaped short root, faint lamina dura and absence of inferior alveolar canals. In small bones of hand and feet, the trabecular pattern is coarse and cystic formation may result in increased fragility and fractures.<sup>16</sup>

Laboratory findings: The peripheral blood smear study shows large hypochromic, microcytic cells, anisocytosis, poikilocytosis with tear drop shaped red cells, target cells, polychromasia and basophilic stippling.<sup>10</sup> Thalassemias are generally classified as hypochromic microcytic anemia; hence the Mean corpuscular volume (MCV) is a key diagnostic indicator. Mean value of Reticulocyte count is increased. The RBC's of Thalassemia major contain increased amount of HbF and thus remain the diagnostic feature of this form of condition.<sup>12,18,19</sup> Mean HbF levels are highly increased with a wide range between 10-25%. Electrophoresis is one of the easy, quick, and efficient diagnostic methodologies for Thalassemia patients.<sup>7</sup>

#### **Management:**

The management of Thalassemia major has undergone significant changes over last two decades. Quality and duration of life of transfusion dependent  $\beta$  Thalassemia patients have been transformed over the last two decades with expectancy increasing well into 3<sup>rd</sup> and 4<sup>th</sup> decades.<sup>18</sup> Nevertheless, life prolongation discloses several complications, partly due to the underlying disorder and partly related to the conventional treatment with blood transfusion and to iron overload.<sup>20</sup> The lifelong management of Thalassemia major involves several considerations:

1. Transfusion regimen: The definition of the optimal transfusion and iron chelation regimen has been the most important advancement in the management of the disorder with the primary objective to keep under control the ineffective erythropoiesis, its consequences and the iron burden. The optimal transfusion regimen involves regular blood transfusion, usually administered every 2-5 weeks, to maintain the pretransfusion Hb level above 9-10.5 gms/dl.<sup>6</sup>
2. Chelation therapy: Patients receiving regular transfusions are likely to develop iron overload. The repeated transfusion causes hemosiderosis,

a pathologic accumulation of iron especially in the liver, the endocrine organs and the heart. This results in organ dysfunction such as diabetes mellitus, congestive heart failure and cardiac arrhythmias. This unfavourable prognosis has been improved by iron chelation therapy. The gold standard of chelation therapy remains the use of Desferoxamine, because its long-term efficacy has been extensively documented in large multicentre trials.<sup>21</sup>

3. Bone marrow transplantation: is the only treatment available to cure Thalassemia. This therapy should be considered in all patients who have a HLA-identical donor. Patients are classified on the basis of their risk factors which have been found to significantly influence the post-treatment outcome. These include – inadequate chelation, presence of liver fibrosis and hepatomegaly.

#### **Conclusion:**

Normal growth of Thalassemia children during the first 10 years of life depends upon the maintenance of hemoglobin levels above 8.5 gms/dl; during this period of child's life, hypoxia may be the main factor retarding growth and the maintenance of Hb levels above 10-11 gms/dl together with adequate iron chelation therapy makes the Beta Thalassemia patients indistinguishable from their non-Thalassemia peers. Therefore regular and repeated blood transfusion along with iron chelation lessens the severity or even prevents orofacial deformities. Therefore, skull and face deformities can be closely related to the patient's age, the intensity of anemia and the beginning of time of treatment.

Conclusively, patients receiving inadequate blood transfusion in childhood will face more bone changes (expansion and deformity) in adolescence, which are a cause of hyperactivity of bone marrow to compensate for chronic anemia. Hence, early diagnosis and regular blood transfusions reduce the prevalence of oro-facial complications and the related psychological trauma.

#### **References:**

1. J Ahmed, UM Seraj, MA Chowdary. An Epidemiological Study of Thalassemia, its quick diagnosis and influence of malaria in Chittagong area of Bangladesh. *Pakistan Journal of Biological Sciences*. 2004; 7 (11): 1953-7.
2. ML Saovaros Savsti, Tran Minh Hieu, Thongperm Munkongdee. Molecular Analysis of  $\beta$ -Thalassemia in South Vietnam American. *Journal of Hematology* October 2002; 71(2): 85-8.
3. AM Hazza'a, G AL-Jamal. Radiographic features of the jaws and teeth in thalassaemia major *Dentomaxillofacial Radiology*.2006; 35 (4): 283-8.
4. Deborah Rund MD, Eliezer Rachmilewitz MD.  $\beta$ -Thalassemia. *N Engl J Med* 2005; 353: 1135-46.
5. AM Hazza'a, Ghaida Al-Jamal. Dental Development in Subjects with Thalassemia Major, *J Contemp Dent Pract* September 2006; 4 (7): 063-070
6. Mahshid Mehdizadeh, Mojdeh Mehdizadeh, Gholamreza Zamani. Orofacial Complications in Patients with Major Beta-Thalassemia, *Dent Res J* 2008; 5(1): 17-20
7. Moutaz Takriti, Mayssoon Dashash. Craniofacial parameters of Syrian children with  $\beta$ -thalassemia. *Journal of Investigative and Clinical Dentistry* 2011; 2: 135-43
8. MA Hollar. The Hair-On-End Sign, *N Engl J Med*, August 2, 2001; 345, No.5,e1
9. Chern JP. et, al.  $\beta$ -Thalassemia Major Births After National Screening Program in Taiwan. *Pediatr Blood Cancer* 2008; 50(1): 58-61
10. Gwendolyn M Clarke, Trefor N Higgins. Laboratory investigation of Hemoglobinopathies and Thalassemias: Review and update. *Clinical Chemistry* 2000; 46:8(B): 1284-90.
11. Baker H, Al-Awamy. Thalassemia syndromes in Saudi Arabia Meta-analysis of local studies. *Saudi Medical Journal* 2000; 21 (1): 8-17.

12. Al-Wahadni AM, Taani DQ, Al-Omari. Dental diseases in subjects with  $\beta$ -thalassemia major, *Community Dent Oral Epidemiol* 2002; 30(6): 418-22
13. Elham SJ. Uvulo-glosso-pharyngeal dimensions in subjects with  $\beta$ -thalassaemia major. *European Journal of Orthodontics* 2002; 24 (6): 699-703.
14. SS Ambekar. The Prevalence and Heterogenity of Beta Thalassemia Mutations in the Western Maharashtra Population: A hospital Based Study. *IJHG* 2001; 1(3): 219-23.
15. S Aggarwal. Status of HFE mutations in thalassemia syndromes in north India, *Ann Hematol* July 2007; 86(7): 483-5.
16. MR Salehi, DD Farhud, TZ Tohidast, M Sahebamee, H Khadem. Prevalence of Orofacial Complications in Iranian Patients with  $\beta$ -Thalassemia Major, *Iranian J Pubi Health*, 2007; 36, No.2: 43-6.
17. HG Poyton, KW Davey. Thalassemia Changes visible in radiographs used in dentistry Oral surgery, *Oral medicine & Oral pathology*.1968; 25, No.4: 564-76.
18. Shah A. Thalassemia Syndromes. *Indian Med Sci*. October 2004; 58 (10): 445-9.
19. Mahshid Mehdizadeh, Mojdeh Mehdizadeh, Gholamreza Zamani. Oro dental Complications in Patients with Major Beta-Thalassemia, *Dent Res J* 2008; 5(1): 17-20
20. Lanzkowsky P. *Manuel of pediatric hematology and oncology*. Elsevier academic press April 2005.
21. Nathan DG, Orkin SH, Thomas Look A, Ginsburg D. "Nathan and Oski's hematology of infancy and childhood". 6th ed. Philadelphia: Saunders; 2003; 1; 281-365.

Source of Support: Nil

Conflict of Interest: No Financial Conflict