

Retention of calcium hydroxide at apical one third of root canal for apexification and continued root development – a clinical case report

Vinay Kumar.G. M.DS* , Reshma Savanoor Hegde. M.D.S , Prashanth Moogi. M.D.S*****

*Senior Lecturer, Department of Conservative Dentistry and Endodontics**Professor and Head of Department of Conservative Dentistry and Endodontics *** Professor, Department of Conservative Dentistry and Endodontics. Kle society's institute of dental sciences, Bangalore Email:gvin_74@hotmail.com

Abstract:

Apexification is defined as a method to induce a calcified barrier in a root with open apex or the continued apical development of an incomplete root in teeth with necrotic pulp. The degree of continued root development is associated with the maintenance of HERS (hertwig's epithelial root sheath) integrity. This case report revealed root closure and apical root development in a tooth with pulp necrosis and chronic apical periodontitis. The novel approach followed was that the intracanal medicament of calcium hydroxide (Metapex, META BIOMED CO., LTD Korea) was placed and left for six months. Later the case was planned for retention of calcium hydroxide at the apical one third followed by obturation. A follow up for a period of 2 years revealed healthy periapical area with additional root development.

Key Words: Apexification, Open Apex, Calcium Hydroxide, Obturation.

E- ISSN
0976 – 1799

Journal of
International
Oral Health

Conservative dentistry
and Endodontics

Original Research

Introduction:

Trauma to the anterior teeth, commonly found among young children accounts for one third of all traumatic injuries in boys and one fourth of all injuries in girls. Tooth fracture constitutes 4% - 5% and luxation injuries 30%-44% of all dental trauma injuries. Because of their position, the anterior teeth tend to bear the brunt of many impact injuries. The injuries may vary from avulsion to intrusion, lateral displacement, fracture or just a concussion. In many cases, the injury causes cessation of tooth development. Because the root development takes place for almost two years after the tooth has erupted into the oral cavity, an incompletely formed apex is one of the most common features seen in traumatized teeth. The patient commonly reports after many years when necrosis of the pulp has caused apical periodontitis or discoloration, causing either pain or compromised esthetics. Inadvertently radiographs reveal an open apex or blunder buss apex¹.

When teeth with incomplete root formation suffer pulp necrosis, the formation of dentin stops, and root development ceases. Consequently, the canal remains large, with thin and fragile walls, and the apex remains open. These features make instrumentation of the canal difficult and hinder the formation of adequate apical stop². Conversely, the possibilities of surgical correction by root-end resection and filling presents management problems when performed in young patients as well as

doubtful prognosis because of fragile apical anatomy, which often implies the need for extensive root resection, thereby considerably reducing the crown /root ratio³. In such cases, in order to allow the condensation of the root filling material and to promote an apical seal, it is imperative to create an artificial apical barrier or induce the closure of apical foramen with calcified tissue (apexification)². In these cases a conservative approach may be adopted by the induction of an apical closure, by the intracanal application of biomaterials to induce the apical and periapical repair, in procedure called apexification³. In this case report, we report retention of calcium hydroxide at apical one third of root canal followed by obturation for closure of root apex and to have continued root development.

Case report:

An 18 year old female patient reported with pain associated with tooth 21. The dental history revealed a traumatic injury to this tooth previously, during fall from stairs. Clinically, there was pain in the anterior facial region and alveolar mucosa associated with sensitivity to palpation. Thermal (Endo-ice; The Hygienic Corporation, Arkon, OH, USA) and electronic (Vitality Scanner; Analytic Technology, Glendora, CA, USA) pulp testing was negative for tooth 21, while adjacent teeth gave normal response. Radiographically tooth 21 exhibited incompletely formed root, characterized by

wide root canal space, thin fragile dentinal walls and increased foraminal opening associated with periapical radiolucency (figure-1).

Diagnosis of incompletely formed root was made. Access cavity was prepared under isolation with rubber dam and wedgets. Working length was established at coinciding with root apex (figure- 2). Chemo mechanical debridement of the root canal was performed using k files. Cleaning and shaping of canal was performed with k files size 60 to 120, with copious irrigation with chlorhexidine gluconate 2% (Loba Chemie) and normal saline. One week later, the patient presented complete resolution of acute symptoms, and treatment using calcium hydroxide intracanal dressing was commenced. After rubber dam isolation further canal debridement with copious irrigation with chlorhexidine and normal saline was done. Canals were dried with sterilized absorbent paper points then calcium hydroxide paste Metapex (META BIOMED CO., LTD Korea) was placed. After placement of a cotton pellet, a provisional protection was performed with glass ionomer cement (figure -3).

Radiographs taken periodically at the end of 3 months and 6 months revealed resolution of periapical radiolucency, evidence of closure of foraminal opening and associated 2mm of additional root development (figure -4&5). Apical 2mm of calcium hydroxide paste metapex was retained in the apical one third of canal (figure-6) and Root canal obturation

was performed with apically molded rolled and heated gutta percha (figure – 7&8). Radiographs taken at the end of one and two years reveal healthy periapical area with additional root development (figure 9&10).

Discussion:

Physiological completion of apical root formation depends on the maintenance of vitality of the tissues that form root dentine and apical periodontal ligament. From an embryonic stand point, Hertwig's epithelial root sheath (HERS) is formed from the cervical loop, between the tissues of dental papilla and the dental follicle. Its inductive action leads to the differentiation of cells of the dental papilla into odontoblasts, which progressively form the root dentine. Upon the onset of root formation, the initial formation of dentine induces fragmentation of the HERS, which then becomes discontinuous and is permeated by cells of the dental follicle. These cells undergo differentiation into cementoblasts close to the newly formed dentine³.

Apexification is defined as a method to induce a calcified barrier in a root with an open apex or the continued apical development of an incomplete root in teeth with necrotic pulp⁴. The degree of continued root development is associated with the maintenance of HERS (Hertwig's epithelial root sheath) integrity. There are controversies in the literature as to its persistence after pulp necrosis, as well as to its reactivation after treatment of periapical inflammatory processes^{5,6}.

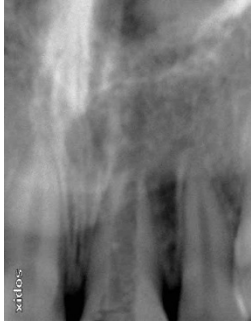

Fig-1: Tooth with incompletely formed root; wide root canal, thin canal walls and extensive periapical lesion.

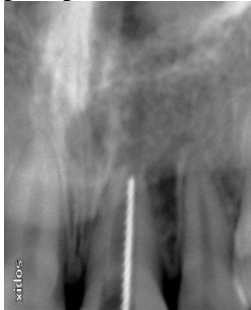

Fig-2: Working length estimation using kfiles

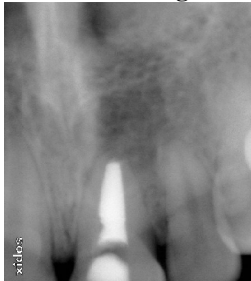

Fig-3: Intracanal dressing of calcium hydroxide placed (Metapex)

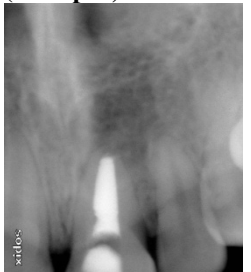


Fig-4 At the end of 3 months there was reduction in foraminal opening and the dimension of periapical radiolucency.

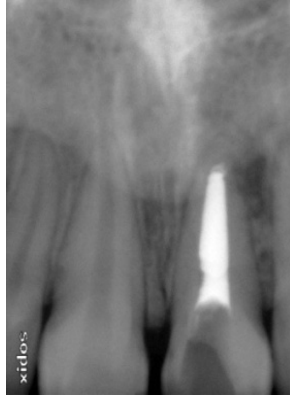

Fig-5 At the end of 6 months there was evidence of closure of foraminal opening, reduction of periapical radiolucency associated with 2mm of additional root development.

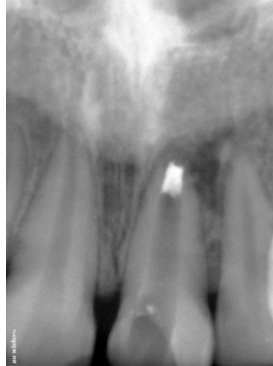


Fig-6 Retention of calcium hydroxide (Metapex) in the apical one third of root canal.

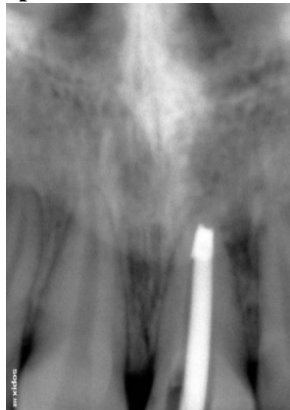

Fig-7 Apically molded rolled and heated gutta percha Mastercone fit checked.

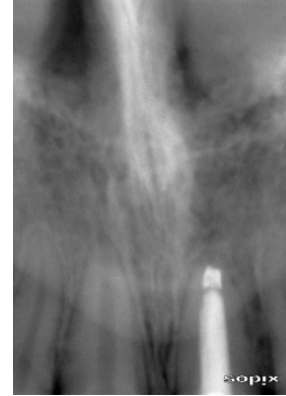

Fig-8 Root canal obturation performed with apically molded rolled and heated gutta percha.

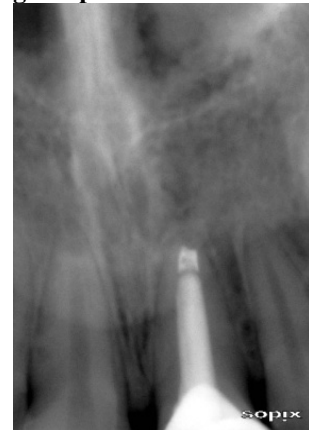

Fig-9 At the end of one year radiograph reveals healthy periapical area with additional root development.

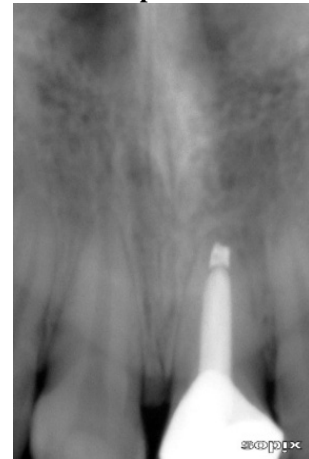


Fig-10 Normal periapical radiographic appearances at the end of 2 year follow up.

This case report revealed root closure and apical root development in a tooth with pulp necrosis and chronic apical periodontitis. Newly formed apical segment radiographically presented irregular, rounded external contour, hypothetically similar to the morphological structure observed by Leonardo³. It might be stated that, in this repair process, a reactivation of HERS remnants occurred which in turn promoted the root formation genetically programmed for that tooth. Thus, it can be speculated that, in this regeneration process, a positive interaction between the HERS and the calcium hydroxide root canal dressing occurred. Therefore, the possible activation of HERS cells by calcium hydroxide should also be undertaken into consideration.

The favorable clinical, radiographic and histological responses obtained with calcium hydroxide are related to the participation of Ca^{++} and OH^- ions in several mechanisms which would provide : (I) control of the inflammatory reaction (by hygroscopic action; formation of calcium proteinate bridges and inhibition of phospholipase); (II) the neutralization of acidic products of osteoclasts (acidic hydrolases and lactic acid); (III) the induction of mineralization (activation of alkaline phosphatase and calcium-dependant ATPases); (IV) the induction of cell differentiation; (V) the depolymerization of endotoxins; and (VI) antibacterial action by means of irreversible damage to DNA, proteins, enzymes and bacterial lipids³.

Calcium hydroxide progressively solubilizes and diffuses into the tissue fluids, especially via the apical

foramen, so it should be periodically renewed. But this case report revealed that there was no solubilization and dissolution of calcium hydroxide over a period of time. This may be attributed to the fact that calcium hydroxide could possibly establish zones of tissue response through the formation of calcium carbonate (CaCO_3) as a result of the reaction of $\text{Ca}(\text{OH})_2$ with tissue CO_2 ^{7,8}. Thus calcium hydroxide would diffuse through the hidden, microscopic spaces of the root canal system, providing continuous disinfection throughout the structure of the dentin, and ultimately obturation, by hardening in place by formation of calcium carbonate^{9, 10}. It can be observed that initially calcium hydroxide applied to root canals acted directly on mineralized dental tissues through passive diffusion of Ca^{++} and OH^- ions. After apical root closure because of the physical and chemical barriers posed by the dentine, dissolution decreased and calcium hydroxide converted into hard setting calcium carbonate which stopped its dissolution.

One visit apexification with a mineral trioxide aggregate (MTA) apical plug also represents an adequate treatment option^{11, 12, 13}. In cases of extreme foraminal openings associated with periapical lesions, as in this case, the orthograde application of MTA presents several technical limitations, resulting in deficient sealing and possibly causing periapical extrusion¹³. Nonetheless, in the MTA reaction, the resulting hydrate was observed to be poorly crystallized and produced a porous material that may be defined as a rigid gel, which may in turn justify the reduced release of Ca^{++} and OH^-

ions to the surrounding medium and hypothetically reduce the inductive action of apical root development. In these circumstances, despite the occurrence of the biological sealing of the foraminal openings, there would be a remote possibility of complimentary apical root development. Calcium hydroxide presents an even greater advantage in this aspect because continued root development coupled with a concomitant wall thickness, can consequently cause a natural root support to occur thus reducing the risk of vertical root fracture from originating in this newly formed mineralized tissue segment³.

Conclusion:

Dental trauma in teeth with incompletely formed roots may cause pulp necrosis, the arrest of root formation and the later development of periapical lesions. Apexification by means of chemo-mechanical debridement and retention of calcium hydroxide at apical one third of root canal is a justified alternative for the biological sealing of an extensive foraminal opening with concomitant repair of periapical lesions and continued apical root development.

References:

- 1) Naseem shah , Ajay logani, Uday bhaskar, Vivek aggrawal, (2008) Efficacy of revascularization to induce Apexification/Apexogenesis in infected, nonvital, immature teeth: a pilot study *Journal of Endodontics*, 8, 919-925.
- 2) Felipe WT ,Felippe MCS, Rocha MJC (2006) The effect of mineral trioxide aggregate on the apexification and peiapical healing of teeth with

- incomplete root formation. *International Endodontic Journal*, 39, 2-9.
- 3) Sores J, Santos S, Cesar P, Silva M, Silveira F, Nunes E, Calcium hydroxide induced apexification with apical root development: a clinical case report. *International Endodontic Journal*, 41, 710-719.
- 4) American association of Endodontists (2003) *Glossary of Endodontic Terms*, 7th edn Chicago, American Association of Endodontists.
- 5) Leonardo MR, Silva LAB, Leonardo RT, Utrilla LS, Assed S (1993a) Histological evaluation of therapy using calcium hydroxide dressing for teeth with incompletely formed apices and periapical lesions, *Journal of Endodontics* 19, 348-52.
- 6) Leonardo MR, Silva LAB, Utrilla LS, Assed S (1993b) Effect of intracanal dressings on repair and apical bridging of teeth with incomplete root formation. *Endodontics and Dental Traumatology* 9, 348-52.
- 7) Holland R, Souza V, Nery MJ, Mello W, Bernabe PFE, Otoboni Filho JA (1979) A histological study of the effect of calcium hydroxide in the treatment of pulpless teeth of dogs *Journal of the British Endodontic Society* 12, 15-23.
- 8) Holland R, de Souza V, Nery MJ, Otoboni Filho JA, Bernabe PF, Dezan Junior E (1999) Reaction of rat connective tissue to implanted dentin tubes filled with mineral trioxide aggregate or calcium hydroxide *Journal of Endodontics* 25, 161-6.
- 9) Bernard, PD, *Therapie Ocalxique*, Editions Maloine, Paris, 1967.
- 10) Plummer, LN; Wigley, TML ; Parkhurst, DL; *The Kinetics of Calcite Dissolution in CO₂ - Water Systems*. *Am J Sci*. 278 : 179-216 (1978)
- 11) Torbinejad M, Chiavian N (1993) Clinical application of mineral trioxide aggregate. *Journal of Endodontics* 25. 197-205
- 12) Seux D, Couble ML, Hartmann DJ, Gauthier JP, Magloire H (1991) Odontoblast-like cytodifferentiation of human dental pulp cells in vitro in the presence of calcium hydroxide-containing cement. *Archives of Oral Biology* 36, 117-28.
- 13) De-Deus G , Coutinho-Filho T (2007) The use of white Portland cement as an apical plug in a tooth with a necrotic pulp and wide-open apex a case report, *International Endodontic Journal*, 40, 462-70